


## ORIGINAL ARTICLE

# Clinical and radiographic outcome following immediate loading and delayed loading of single-tooth implants: Randomized clinical trial

Björn Gjelvold, DDS<sup>1,2</sup>  | Jenö Kisch, OD.h.c, DDS<sup>1</sup> |  
Bruno Ramos Chrcanovic, DDS, MSc<sup>2</sup> | Tomas Albrektsson, MD, PhD<sup>2,3</sup> |  
Ann Wennerberg, DDS, PhD<sup>2</sup>

<sup>1</sup>Clinic for Prosthodontics, Centre of Dental Specialist Care, Malmö, Sweden

<sup>2</sup>Department of Prosthodontics, Faculty of Odontology, Malmö University, Malmö, Sweden

<sup>3</sup>Department of Biomaterials, University of Gothenburg, Sweden

## Correspondence

Björn Gjelvold, Clinic for Prosthodontics, Centre of Dental Specialist Care, Spårväggsgatan 12, SE-214 27 Malmö, Skåne, Sweden.

Email: bjorn.gjelvold@skane.se;  
bjorn.gjelvold@gmail.com

## Funding information

Region Skåne and Folk tandvården Skåne AB (Public Dental Care Service, Skania, Sweden)

## Abstract

**Background:** Immediate loading of single implants is generally considered a reliable procedure.

**Purpose:** The objective of the present prospective randomized clinical study was to compare the overall treatment outcome following immediate loading (IL) and delayed loading (DL) of single implants after 1 year of follow-up.

**Materials and Methods:** Patients with a missing maxillary tooth (15-25) were randomly assigned to IL or DL. The protocol included implant installation in healed sites, immediate loading, delayed loading, temporary screw-retained restoration, and replacement with a permanent single implant crown. Outcome measures were implant survival, marginal bone level, soft tissue changes, papillae index, pink, and white esthetic score (PES and WES), patient judged aesthetics, and oral health impact profile (OHIP-14).

**Results:** Implant survival rate was 100% and 96% for IL and DL, respectively. Implant success rate was 96% and 88% for IL and DL, respectively. Statistically significant lower papilla index scores were found in the IL group at temporary crown and definitive crown placement. An overall statistically significant improvement after 12 months for PES, WES and OHIP-14 was found.

**Conclusion:** This prospective randomized study showed that single implants in the maxilla can present satisfactory results with respect to either immediate loading or delayed loading after 12 months.

## KEYWORDS

immediate function, immediate loading, implant, implant-supported crown, implant survival, patient satisfaction, randomized controlled trial

## 1 | INTRODUCTION

The main purpose of dental implants is to act as anchoring elements for prosthetic restorations, replacing one or several lost teeth. Replacing a single tooth can be a challenging endeavor with many factors to consider for the clinician and patient alike. The use of single implants has become a predictable and successful treatment option<sup>1</sup> and in certain situations considered the most cost-effective alternative of other

options when treating gaps.<sup>2</sup> The high success rates have led to further development of the original delayed loading protocol. Immediate, early and delayed loading protocols have been described for single implants.<sup>3</sup> Also the term functional (occlusal) or nonfunctional (nonocclusal) immediate loading has been introduced.<sup>3</sup> Predictable bone integration and high survival rates have been reported for immediate loading of single implants in the anterior maxilla.<sup>4</sup> However, it should be stressed that although high survival rates have been reported, more failures are to

be expected following immediate loading of single implants.<sup>3</sup> Sufficient primary implant stability<sup>5</sup> and the avoidance of eccentric contacts are some factors that has been pointed out as important, for ensuring positive outcome of single implants.

In addition, soft-tissue and aesthetic outcomes are important, and a number of clinical studies focused on these issues for single-implant restorations in the anterior region.<sup>6–10</sup> The immediate loading procedure results in less disturbance of the peri-implant soft tissues than the two-stage protocol. A study by Luongo et al.<sup>11</sup> observed that repeated abutment changes do not alter bone levels, however the effect on soft-tissue healing and the additional effect from the use of intermediate temporary restoration to shape the implant crown emergence profile remain sparsely documented. Different scales have been developed for soft-tissue and aesthetic evaluations, such as the papilla index,<sup>12</sup> the Pink Esthetic Score,<sup>13</sup> and the White Esthetic Score.<sup>14</sup>

Improving patient satisfaction is of vital importance for many dental treatments and should also be in focus when different treatment protocols are evaluated. Changes in oral health-related quality of life (OHRQoL) can be assessed by the Oral Health Impact Profile-14 (OHIP-14).<sup>15</sup> Other studies have demonstrated an improvement in the OHRQoL between the preoperative and postoperative condition following immediate loading.<sup>6,7</sup> Patient-centered outcomes before, after and during delayed and immediate loading treatment procedure is scarcely documented.<sup>3</sup>

The purpose of this prospective randomized clinical study was to compare implant survival, patient satisfaction, radiographic, clinical, and aesthetic outcomes following immediate loading (IL) and delayed loading (DL) of single dental implants in the maxillary aesthetic zone, after 1-year of follow-up.

## 2 | MATERIALS AND METHODS

### 2.1 | Patient selection

Prior to patient inclusion a sample size of 50 patients, randomized to either IL or DL, was determined as acceptable to reach the level of required statistical power. Patients of at least 18 years of age in need of one or more single-tooth replacements at the Centre of Dental Specialist Care, Malmö between April 2011 and April 2014 were considered for inclusion in the present study. The single-tooth replacement needed to be an incisor, canine or premolar of maxillae with adjacent natural teeth. Exclusion criteria were general contraindications for oral surgery, patients with inadequate oral hygiene, and need for bone grafting or ridge augmentation at the implant site. For the IL-group it was decided to exclude implants with an insertion torque below 30 Ncm.

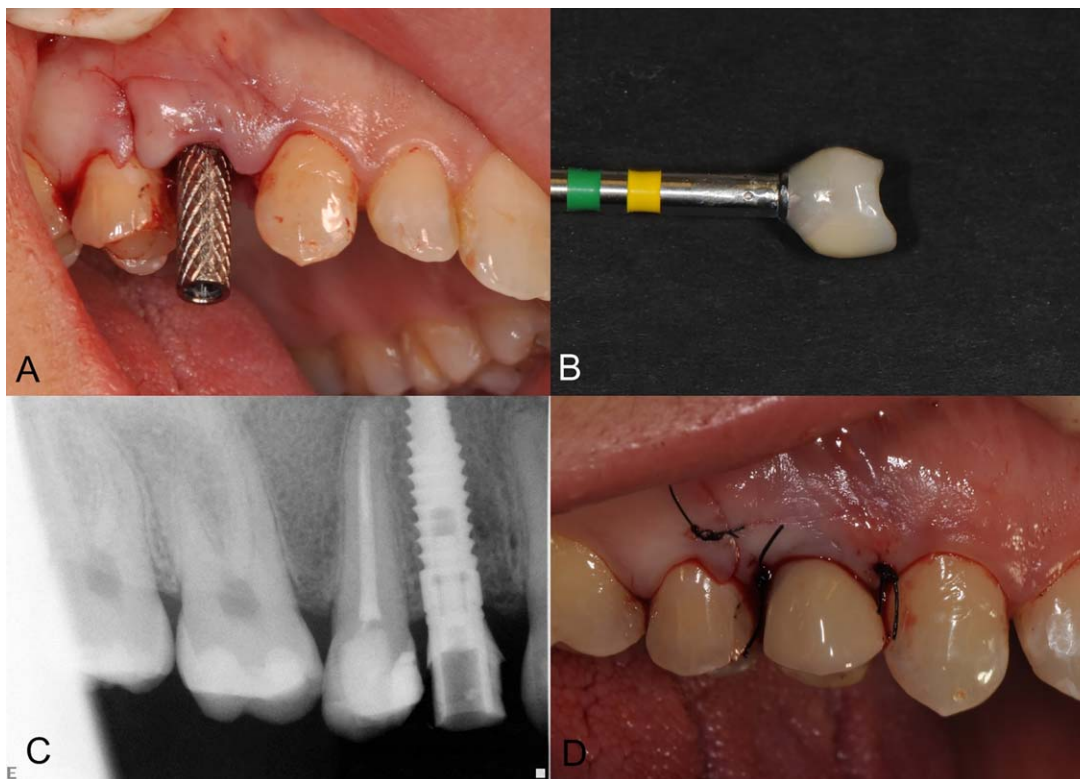
Patients were thoroughly informed about the treatment. The study was conducted in accordance with the Helsinki declaration of 1975 as revised in 2000,<sup>16</sup> and all patients signed a written informed consent. The study protocol was approved by the Regional Ethical Review Board in Lund, Sweden (Dnr 2011/125). ClinicalTrials.gov ID: NCT02770846.

### 2.2 | Treatment group procedures

For the patients willing to participate in the study, a clinical examination was done prior to randomization. Periapical and panoramic radiographs were used to initially evaluate the implant site. For patients eligible for the study, bone quantity and quality of the treated surgical sites were classified at the time of surgery according to the Lekholm and Zarb 1985 classification.<sup>17</sup> Patients were assigned to one of the two study groups, IL or DL, using a closed randomization method with sealed envelopes. The surgeon was blinded with regard to treatment group assignment.

All patients were consecutively treated with Tapered Internal implants (BioHorizons, Birmingham, Alabama), placed in healed bone (4 months or more after tooth loss), according to a standardized surgical procedure. All implant sites were free from clinical signs of inflammation. Prophylactic antibiotic therapy was prescribed to all patients (phenoxymethylpenicillin, 500 mg 8/8 hours, Kåvepenin, Meda AB, Solna, Sweden), beginning 1 hour before surgery and extending for 7 days. Surgery was performed under local anesthesia (Xylocaine with 2% adrenaline, Dentsply Pharmaceutical, York, Pennsylvania). An incision was placed at the mid-crest and a mucoperiosteal flap was raised with a vertical releasing incision. All implants were installed according to the recommendations given by the implant manufacturer. After installation, the implant was inspected for the presence of buccal fenestrations or dehiscences. Exposure of more than 1 mm of the implant excluded the patient from the study. Defects <1 mm were covered with autogenous bone chips collected during the implant bed preparation, and no membranes were used. Postoperatively, the patients were instructed to rinse twice daily with a solution of 0.2% chlorhexidine for 14 days and to take analgesics in case of need (paracetamol 500 mg 6/6 hours, Alvedon, GlaxoSmithKline AB, Solna, Sweden). Sutures were removed after 2 weeks. All fixture installations were performed at the Centre of Dental Specialist Care, Malmö, Sweden, by the second author (J.K.).

In the IL group, the implants were immediately loaded with a screw-retained temporary crown. A titanium temporary abutment (BioHorizons, Birmingham, Alabama) with a composite crown (Sinfony, 3M ESPE, Maplewood, Minnesota) were used (Figure 1). The provisional restorations were adjusted to a light centric contact and free from eccentric contacts with the opposing teeth before the polishing procedures. The restorations were tightened to 15 Ncm and the mucoperiosteal flaps were adapted to the crown before wound closure. The patients were instructed to avoid exerting force on the temporary restoration. In the DL group, the patients underwent a two-stage surgery procedure with a minimum healing period of 4 months before a screw-retained temporary crown was fabricated using the same materials as in the IL group. The temporary crown shape and emergence profile were modified until the patients were satisfied with the crown and soft tissue appearance. Prosthetic procedures for definitive crowns were initiated after 2 months in the IL group and after 4–6 months in the DL group from the time of fixture installation. An implant-level impression was performed using a customized impression coping in such a way that the obtained emergence profile from the temporary restorations could be transferred to the definitive restoration, according to the method described elsewhere.<sup>18</sup> The definitive crown consisted of an



**FIGURE 1** Temporary crown IL A, Titanium temporary abutment; B, Temporary crown after polishing; C, Radiograph of temporary crown; D, Temporary crown seated and mucosa sutured

individually fabricated zirconia abutment (I-butment, Biomain AB, Helsingborg, Sweden), with a titanium base (Medentica GmbH, Hügelsheim, Germany), being cemented- or screw-retained (Figure 2). The cemented-retained crowns and titanium bases were cemented with a bonding agent (Z-Prime Plus, Bisco, Schaumburg, Illinois) and dual-curing resin cement (Variolink, Ivoclar-Vivadent, Schaan, Liechtenstein). All crowns were veneered (GC Initial, GC EUROPE N.V., Leuven, Belgium) by the same dental technician. All prosthetic procedures were accomplished by the first author (B.G.).

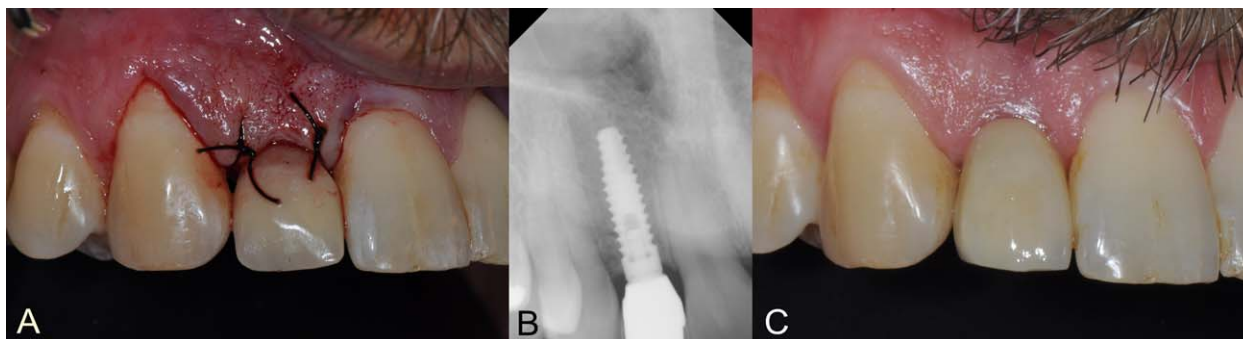
### 2.3 | Follow-up appointments

After completion of the final restoration, the patients' dental hygiene were followed up by a dental hygienist within 6 months. The patients

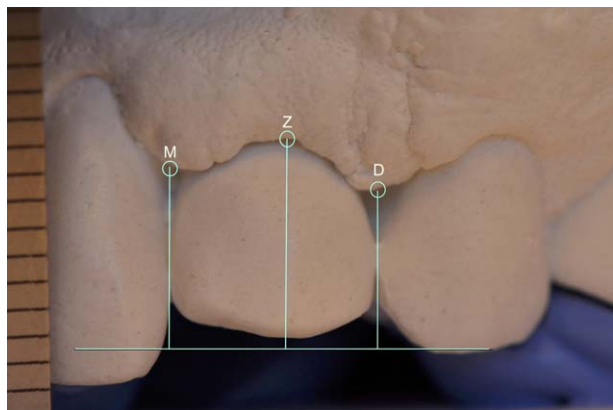
were asked to attend a clinical and radiographic follow-up examination at 3, 6, and 12 months after definitive crown placement. The baseline for the radiographic follow-up was the day of the implant surgery, and the baseline for the aesthetic outcomes was the day of the placement of the definitive crown. The examinations were conducted by the same examiner responsible for the prosthetic treatment.

### 2.4 | Hard and soft tissue evaluation

Digital intraoral periapical radiographs (Schick Digital X-ray Sensor, Sirona, Salzburg, Austria) were taken immediately after surgery, and after 6 and 12 months, always using the long-cone parallel technique. The marginal bone level was measured after calibration with the inter-thread distance of the Tapered Internal implants (1.00 mm).



**FIGURE 2** A, Temporary crown; B, Radiograph of final restoration; C, Final restoration



**FIGURE 3** Photographic measurements of soft tissue changes. The casts were positioned in front of the camera in a reproducible manner by individual bite impressions. A reference line was used to measure vertical change in mesial papilla (M), distal papilla (D), and the zenith position (Z)

Measurements were taken from the implant-abutment junction to the marginal bone level, at both mesial and distal sides of each implant, and then the mean value of these two measurements was considered. Marginal bone loss (MBL) was calculated by comparing bone-to-implant contact levels to the radiographic baseline examination. The Image J software (National Institute of Health, Bethesda) was used for all measurements.

Furthermore, resonance frequency analysis (RFA) was performed at implant installation and at definitive crown placement according to the manufacturer's instructions (Osstell ISQ, Osstell AB, Göteborg, Sweden). In the present study, the RFA was used to monitor the implant stability between implant installation and completion of the final restoration, to determine if there were any early signs of failure.

The gingival index was scored for each implant at each follow-up examination, according to Löe and Silness.<sup>19</sup>

The papilla index,<sup>12</sup> gingival zenith and papilla levels around the implant restoration were measured on each follow-up examination. The vertical changes in gingival zenith positions were defined as the linear distance from the gingival zenith to the reference line and for papilla levels as the linear distance from the papilla tip to the reference line (Figure 3). Casts were made after receiving and before removing the temporary restoration, at completion of the permanent restoration, and after 3, 6, 12 months. Study casts were photographed (Nikon D7000, Nikon Corporation, Tokyo, Japan) together with a 1-mm precision ruler. The Image J software (National Institute of Health, Bethesda) were used for all measurements.

## 2.5 | Aesthetic assessment

Intraoral photographs from the aesthetic baseline and follow-up appointments were used to register the pink esthetic score (PES), according to the technique described by others.<sup>13</sup> Photographs from the final follow-up appointment were used to calculate the white esthetic score (WES).<sup>14</sup>

Cosyn et al. have defined (almost) perfect outcome for PES and WES as  $PES \geq 12$  and  $WES \geq 9$ , respectively, and aesthetic failure as  $PES \leq 7$  and  $WES \leq 5$ , respectively.<sup>20</sup>

## 2.6 | Patient-centered outcome

The OHRQoL was calculated using the Swedish validated version of the Oral Health Impact Profile (OHIP-14) questionnaire.<sup>15</sup> The additive score is obtained by summation of the response codes for the 14 items. This gives a range from 14 to 70, where a higher score indicates poor OHRQoL. The questionnaires were completed at the beginning of the treatment, on the day when the patients received a temporary crown, and at 6 and 12 months after the definitive crown placement. Moreover, the patients' satisfaction with the final restoration was assessed 12 months after the definitive crown placement, by using a visual analog scale (VAS). The patients marked their satisfaction in a non-numerical 100 mm line ranging from "not at all satisfied = 0" (left) to "very satisfied = 100" (right), for each implant. They were asked the following question: (1) "Are you satisfied with the aesthetic result of your treatment?" Each response was given a numerical value by measuring in millimeters the distance from the left end of the line.

## 2.7 | Success and survival

Implant success and survival were evaluated according to Albrektsson.<sup>21</sup>

## 2.8 | Statistics

All data were statistically analyzed by one examiner, who did not take part in any of the clinical procedures. The software used was the Statistical Package for the Social Sciences (SPSS) version 22 (SPSS Inc., Chicago, Illinois). The data were tabulated, and from these measurements mean, standard deviation (SD), minimum and maximum were calculated. Kolmogorov-Smirnov test was performed to evaluate the normal distribution of the variables, and Levene's test evaluated homoscedasticity. The performed tests for two independent groups, three or more independent groups, and two dependent groups were Student's *t*-test or Mann-Whitney test, one way ANOVA or Kruskal-Wallis test, and paired-samples *t*-test or Wilcoxon signed-rank test, respectively, depending on the normality. Pearson's chi-squared or Fisher's exact test was performed for categorical variables, depending on the expected count of events in a  $2 \times 2$  contingency table. Correlation and linear regression were performed to check the relationship between the patients' satisfaction (VAS), PES/WES scores and OHIP-14. The degree of statistical significance was considered  $P < .05$ .

## 3 | RESULTS

A total of 62 patients were initially allocated to the study. Twelve patients were not included in the study for the following reasons: four patients did not want treatment for economic reasons, three patients presented extensive osseous defects that would require a bone graft in order to make the insertion of an implant possible, one patient desired

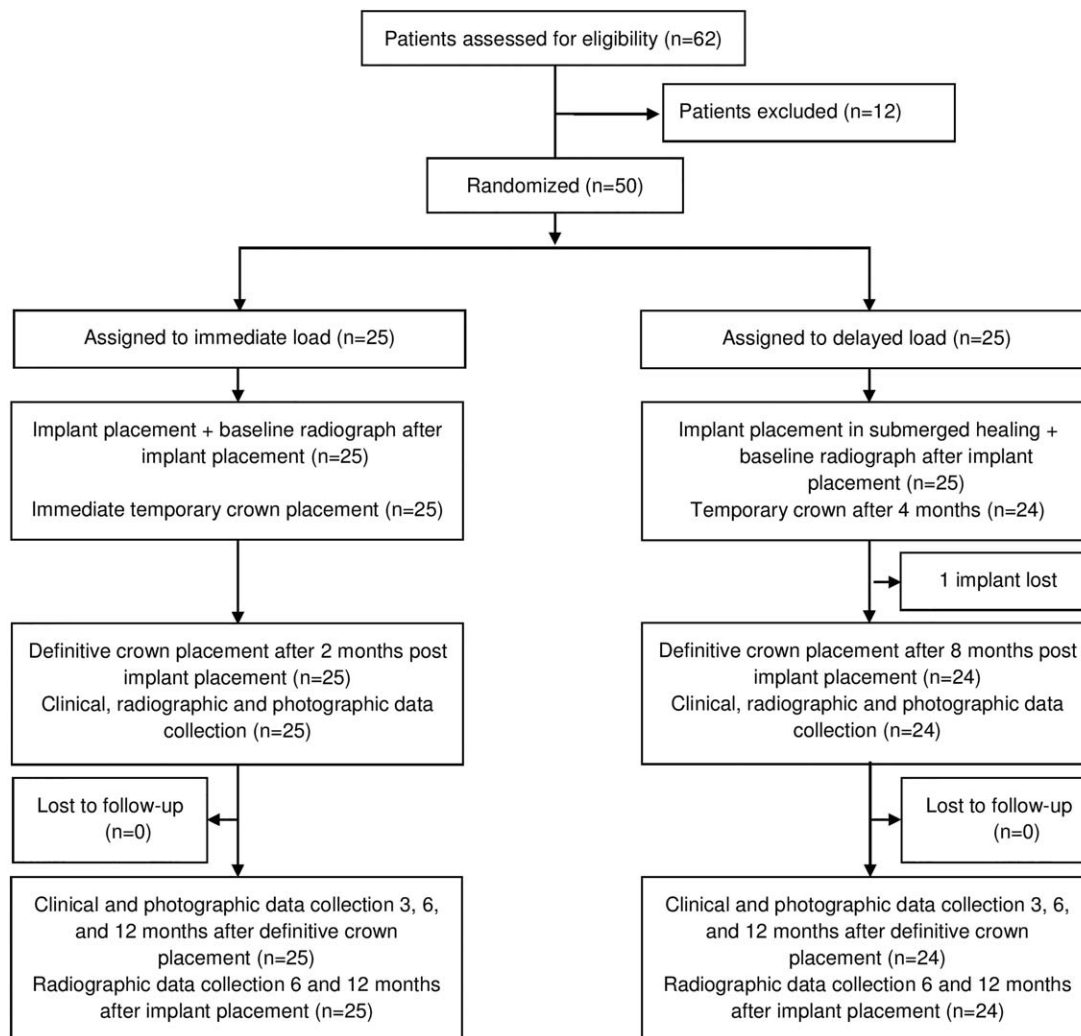


FIGURE 4 Clinical trial outline of study participants

a tooth supported bridge instead of an implant, three patients decided to leave the study before surgery. The remaining 50 patients were included in the study, 25 randomly allocated to each group. In the IL-group, all implants reached the minimum insertion torque of 30 Ncm.

There were no drop-outs and all patients attended the follow-up visits, except for two patients who missed the 6-month follow-up. One implant was lost 3 months after surgery in the DL group, resulting in an implant survival rate of 100% and 96% for IL and DL, respectively. Implant success rate was 96% and 88% for IL and DL, respectively. No complications to the implants or implant supported crowns occurred during the 1-year follow-up period. The clinical trial outline is shown in Figure 4. Details about the patients and treatment specifications at the time of the implant surgery are described in Table 1.

### 3.1 | Hard and soft tissue evaluation

The mean  $\pm$  SD Implant Stability Quotient (ISQ) values at fixture installation for IL and DL were  $73.64 \pm 7.78$  and  $68.86 \pm 8.36$ , respectively ( $P < .015$ , Mann-Whitney test). At completion of the final restoration the mean  $\pm$  SD ISQ values were  $74.64 \pm 6.31$  and  $73.62 \pm 5.05$  for IL

and DL, respectively. It should be noted that completion of the final restoration did occur at different time points for the two groups. Outcome for MBL, gingiva index and papilla index for IL and DL are shown in Table 2. In both the IL and DL group there were a statistically significant difference in MBL between 0-6 months and 7-12 months ( $P = .000$  and  $P = .000$ , Wilcoxon signed-rank test) with IL implants displaying the least loss of marginal bone. The mean  $\pm$  SD (min-max) MBL between smokers ( $n = 7$ ) and nonsmokers ( $n = 42$ ) at 6 months was  $-0.87 \pm 0.81$  mm ( $-1.99-0.00$ ) and  $-0.45 \pm 0.45$  mm ( $-2.04-0.57$ ), respectively ( $P = .424$ , Mann-Whitney test). The values at 12 months were  $-0.93 \pm 0.80$  mm ( $-2.05-0.00$ ) and  $0.58 \pm 0.48$  mm ( $-2.37-0.23$ ) for smokers and nonsmokers, respectively ( $P = .408$ , Mann-Whitney test).

Soft tissue changes for gingival zenith and papilla levels around the implant restoration for IL and DL are shown in Table 3. The mean distance until mesial and distal papilla reached a complete papilla fill (papilla fill according to the papilla index) for IL and DL were  $0.77 \pm 0.71$  mm and  $0.60 \pm 0.74$  mm, respectively ( $P = .264$ , Mann-Whitney test) at the 12-month follow-up. Patients with a complete papilla fill on both mesial and distal sides in IL and DL after 12 months were 28% and 46%, respectively ( $P = .244$ , Fisher's exact test).

TABLE 1 Characteristics and treatment specifications of 50 patients treated with a single implant with immediate or delayed loading

Variable	Immediate loading	Delayed loading	P-value
<i>Implant surgery</i>			
Mean age $\pm$ SD (min, max), (years)	40.8 $\pm$ 13.3 (19.0-66.6)	40.9 $\pm$ 15.5 (18.5-76.7)	.973*
Men/women	14/11	6/19	.021†
Smokers/Nonsmokers	2/23	6/19	.247††
Bruxers/Nonbruxers	2/23	0/25	.490††
Diabetic/Nondiabetic	0/25	0/25	-
Reason for missing tooth			
Trauma	15	12	
Agnesia	3	4	
Advanced caries	5	5	
Root resorption	2	2	
Apical destruction	0	2	
Implant diameter: 3.8/4.6 mm	18/7	22/3	
Implant length: 10.5/12/15 mm	0/16/9	2/14/9	
Bone quantity: A/B/C/D/E	5/20/0/0/0	2/21/2/0/0	
Bone quality: 1/2/3/4	0/13/12/0	0/6/18/1	
Mean installation torque $\pm$ SD	34.04 $\pm$ 4.89	30.24 $\pm$ 7.92	.062**
<i>Prosthetic treatment</i>			
	mean days $\pm$ SD after implant surgery		
Abutment connection	-	140 $\pm$ 3	
Definitive prosthesis	103 $\pm$ 5	228 $\pm$ 59	
Screw-retained/cemented	15/10	15/9	

SD, standard deviation.

\*Student's t-test. \*\*Mann-Whitney test. †Pearson Chi-squared test. ††Fisher's exact test.

### 3.2 | Aesthetic outcomes

An overview of PES and WES outcomes for IL and DL can be seen in Table 4, with no statistically significant differences between the two loading protocols.

There was a statistically significant improvement in PES between initial evaluation and after 1 year for both IL and DL ( $P = .001$  and  $P = .002$ , Wilcoxon signed-rank test) and also for WES ( $P = .008$  and  $P = .001$ , Wilcoxon signed-rank test).

Perfect outcome after 12 months in the IL and DL groups were found for PES in 32.0% and 37.5% of the cases and for WES in 28.0% and 29.2% of the cases, respectively. Aesthetic failures in the IL and DL groups were found for PES in 16.0% and 12.6% of the cases and for WES in 4.0% and 8.3% of the cases, respectively.

### 3.3 | Patient-centered outcomes

OHIP-14 and VAS outcome for IL and DL are summarized in Table 5. For both groups, the mean additive OHIP-14 score at the initial appointment for male and female were  $21.40 \pm 6.54$  ( $n = 20$ ) and

$27.47 \pm 9.73$  ( $n = 30$ ), respectively ( $P = .018$ , Mann-Whitney test). At the final follow-up, the mean additive OHIP-14 score for male and female were  $15.7 \pm 2.66$  ( $n = 20$ ) and  $16.10 \pm 3.74$  ( $n = 29$ ), respectively ( $P = .929$ , Mann-Whitney test). There was an overall statistically significant improvement in OHRQoL, assessed by OHIP-14, between initial appointment and temporary crown placement for IL and DL ( $P = .000$  and  $P = .002$ , Wilcoxon signed-rank test). The relationship between VAS and final (12-month) PES score was very weak ( $R = 0.033$ ,  $R^2 = 0.001$ ,  $P = .825$ ; Pearson correlation). The linear regression analysis showed that for every 1 point increase in PES, the VAS value increased by 0.141 points. The relationship between VAS and the final (12-month) WES score was also very weak ( $R = 0.061$ ,  $R^2 = 0.004$ ,  $P = .678$ ; Pearson correlation). The linear regression analysis showed that for every 1 point increase in WES, the VAS value increased by 0.471 points.

For both groups, the relationship VAS and final (12-month) additive OHIP-14 score was moderate ( $R = 0.404$ ,  $R^2 = 0.163$ ,  $P = .004$ ; Pearson correlation). The linear regression analysis showed that for every 1 point increase in OHIP-14, the VAS value decreased 1.225 points.

TABLE 2 MBL, gingiva index, and papilla index outcomes

Variable	Immediate loading	Delayed loading	P-value
<i>MBL (mm)</i>	mean ± SD (min, max)	mean ± SD (min, max)	
0-6 months	-0.51 ± 0.50 (-1.80, 0.57)	-0.51 ± 0.56 (-2.04, 0.22)	.589**
7-12 months	-0.07 ± 0.28 (-0.37, 0.79)	-0.18 ± 0.41 (-0.37, 1.22)	.332**
0-12 months	-0.57 ± 0.52 (-2.05, 0.21)	-0.69 ± 0.57 (-2.37, 0.18)	.468*
<i>Gingiva Index</i>			
Initial appointment	1.24 ± 0.52 (1, 3)	1.36 ± 0.70 (1, 3)	.648**
Temporary crown placement	1.32 ± 0.56 (1, 3)	1.25 ± 0.44 (1, 2)	.754**
3 months of definitive crown	1.08 ± 0.28 (1, 2)	1.00 ± 0.00 (1, 1)	.161**
6 months of definitive crown	1.04 ± 0.20 (1, 2)	1.00 ± 0.00 (1, 1)	.328**
12 months of definitive crown	1.12 ± 0.33 (1, 2)	1.04 ± 0.20 (1, 2)	.322**
<i>Papilla index, mesial</i>			
Temporary crown placement	0.72 ± 0.79 (0, 2)	1.62 ± 0.82 (0, 3)	<.001**
Before temporary crown removal	1.80 ± 0.91 (0, 4)	2.46 ± 0.66 (1, 3)	.005**
Definitive crown placement	1.88 ± 0.97 (0, 3)	2.29 ± 0.80 (0, 3)	.121**
6 months of definitive crown	2.38 ± 0.65 (1, 3)	2.43 ± 0.79 (0, 3)	.544**
12 months of definitive crown	2.56 ± 0.51 (2, 3)	2.63 ± 0.58 (1, 3)	.533**
<i>Papilla index, distal</i>			
Temporary crown placement	0.72 ± 0.54 (0, 2)	1.38 ± 0.82 (0, 3)	.003**
Before temporary crown removal	1.28 ± 0.84 (0, 3)	2.04 ± 0.86 (0, 3)	.004**
Definitive crown placement	1.24 ± 0.88 (0, 3)	2.08 ± 0.83 (0, 3)	.002**
6 months of definitive crown	1.75 ± 0.85 (0, 3)	2.13 ± 0.87 (0, 3)	.113**
12 months of definitive crown	2.12 ± 0.67 (1, 3)	2.25 ± 0.85 (0, 3)	.366**

MBL, marginal bone loss (negative values represent bone loss); SD, standard deviation.

\*Student's t-test. \*\*Mann-Whitney test.

TABLE 3 Soft tissue changes

Variable	Immediate loading	Delayed loading	P-value
<i>Soft tissue changes: mesial papilla (mm)</i>	mean ± SD (min, max)	mean ± SD (min, max)	
During temporary crown	0.35 ± 0.54 (-0.63, 1.87)	0.30 ± 0.45 (-0.36, 1.42)	.810**
At change to definitive crown	-0.02 ± 0.30 (-0.72, 0.65)	-0.07 ± 0.34 (-0.76, 0.47)	.920**
<i>Changes from definitive crown placement</i>			
3 months	0.24 ± 0.39 (-0.46, 1.28)	0.25 ± 0.51 (-1.05, 1.31)	.953*
6 months	0.45 ± 0.50 (-0.31, 1.58)	0.44 ± 0.47 (-0.37, 1.42)	.922*
12 months	0.74 ± 0.70 (-0.36, 2.35)	0.60 ± 0.58 (-0.26, 2.40)	.522**
<i>Soft tissue changes: distal papilla (mm)</i>			
During temporary crown	0.04 ± 0.70 (-2.10, 1.33)	0.27 ± 0.57 (-1.16, 1.13)	.224*
At change to definitive crown	-0.05 ± 0.32 (-0.73, 0.69)	-0.18 ± 0.50 (-1.49, 0.47)	.646**
<i>Changes from definitive crown placement</i>			
3 months	0.30 ± 0.44 (-0.47, 1.41)	0.24 ± 0.42 (-0.33, 1.34)	.682**
6 months	0.52 ± 0.41 (-0.12, 1.34)	0.37 ± 0.44 (-0.42, 1.30)	.194**
12 months	0.63 ± 0.48 (-0.22, 1.49)	0.50 ± 0.60 (-1.24, 1.71)	.406*
<i>Soft tissue changes: gingival zenith (mm)</i>			
During temporary crown	-0.01 ± 0.55 (-1.13, 1.47)	0.11 ± 0.45 (-0.69, 0.97)	.423*
At change to definitive crown	-0.16 ± 0.51 (-1.43, 0.70)	-0.30 ± 0.50 (-1.37, 0.58)	.332*
<i>Changes from definitive crown placement</i>			
3 months	0.09 ± 0.31 (-0.40, 0.65)	0.24 ± 0.42 (-0.53, 1.07)	.164*
6 months	0.11 ± 0.29 (-0.31, 0.82)	0.30 ± 0.42 (-0.45, 1.37)	.075*
12 months	0.10 ± 0.38 (-0.75, 0.92)	0.32 ± 0.52 (-0.54, 1.37)	.088*

SD, standard deviation, Soft tissue change—positive values represent a gain in soft tissue.

\*Student's t-test.

TABLE 4 Aesthetic outcomes

Variable	Immediate loading	Delayed loading	P-value
PES	mean $\pm$ SD (min-max)	mean $\pm$ SD (min, max)	
Definitive crown placement	8.56 $\pm$ 2.27 (2-13)	9.42 $\pm$ 2.98 (4-14)	.262*
3 months of definitive crown	9.32 $\pm$ 2.14 (3-13)	10.08 $\pm$ 2.52 (5-14)	.180**
6 months of definitive crown	9.75 $\pm$ 2.36 (3-14)	10.33 $\pm$ 2.68 (5-14)	.190**
12 months of definitive crown	10.36 $\pm$ 2.46 (3-14)	10.67 $\pm$ 2.32 (5-14)	.700**
WES			
Definitive crown placement	7.00 $\pm$ 1.41 (4-10)	7.00 $\pm$ 1.64 (4-10)	.861**
3 months of definitive crown	7.24 $\pm$ 1.36 (4-10)	7.54 $\pm$ 1.74 (4-10)	.413**
6 months of definitive crown	7.50 $\pm$ 1.35 (4-10)	7.54 $\pm$ 1.62 (4-10)	.759**
12 months of definitive crown	7.76 $\pm$ 1.30 (5-10)	7.87 $\pm$ 1.39 (5-10)	.724**

SD, standard deviation.

\*Student's *t*-test. \*\*Mann-Whitney test.

## 4 | DISCUSSION

The aims of the present study were to evaluate implant survival, patient satisfaction, radiographic, clinical, and aesthetic outcomes following immediate loading and delayed loading of single dental implants placed in the maxilla, until 1 year of follow-up. The DL implants presented a lower survival rate 96%, opposed to 100% for the IL implants, due to the early loss of one implant. The patient who lost an implant was a smoker, considered to be a risk factor for early implant loss.<sup>22</sup> The survival rate for immediate loading was similar to the ones found in other single-implant studies.<sup>5,23</sup>

Others have found that higher ISQ values can be correlated to an increase in installation torque, increased implant diameter and sex.<sup>24</sup> The statistically significant higher ISQ value at implant installation for the IL-group may have been influenced by these factors.

Bone resorption occurred in both groups during the observation period. The greater initial bone loss seen in both groups (0-6 months) could be related to the bone remodeling process initiated after fixture installation.<sup>25</sup> The amount of bone loss correspond the findings of a previous study evaluating immediate loading and the same implant system.<sup>23</sup> The lack of statistically significant difference for MBL between groups seems to indicate that immediate loading in the present study did not affect the MBL in relation to delayed loading during the 1 year of function. However, it is a matter of debate whether there could be a difference under different circumstances, such as larger study groups followed by a longer period.

The statistically significant difference in papilla index between groups could be explained by the differences in time between implant surgery and definitive crown placement for the two groups, even differences in flap adaptation and suturing may have played a role as well. Moreover, the DL group may present a higher score due to the reshaping of the emergence profile until patient satisfaction was reached. Others have suggested that such soft tissue conditioning by customizing the shape and contour of a provisional restorations in the aesthetic zone helps the achievement of a better aesthetic outcome.<sup>26</sup> It is expected that a longer follow-up period than the one observed in the present study could result in additional papilla formation.<sup>12</sup> Concerning soft-tissue changes, there were no statistically significant differences between the two groups. There was an overall tendency of the papilla to gradually increase in height, correlating to the changes found in the papilla index score. The gradual increase in aesthetics and also changes in soft tissue shape may be explained by the gradual papillae formation and the healing process of the mucosa over time.<sup>27</sup> It is expected after placement of implant crowns in edentulous sites that the PES will automatically improve in correlation with wound healing and papillae formation, as many of the evaluation parameters are related. Also, an increase in the WES can be related to the soft tissue healing and adaptation, as the perception of the crown shape and contour may change in the areas in close proximity with the soft tissue. The final PES and WES found in this study for both groups are comparable with the findings reported by others.<sup>6,28</sup>

The statistically significant improvement of OHIP-14 between pre-treatment and after receiving a temporary crown for both groups could

TABLE 5 Patient-centered outcomes

Variable	Immediate loading	Delayed loading	P-value
OHIP-14 additive	mean $\pm$ SD (min-max)	mean $\pm$ SD (min, max)	
Initial appointment	26.68 $\pm$ 9.30 (15-46)	23.40 $\pm$ 8.64 (14-52)	.162**
Temporary crown placement	18.64 $\pm$ 5.32 (14-34)	18.67 $\pm$ 9.06 (14-57)	.383**
6 months of definitive crown	16.92 $\pm$ 4.68 (14-30)	16.48 $\pm$ 7.09 (14-48)	.346**
12 months of definitive crown	16.48 $\pm$ 3.87 (14-29)	15.38 $\pm$ 2.58 (14-25)	.385**
VAS			
12 months of definitive crown	89.6 $\pm$ 9.5 (70-100)	87.9 $\pm$ 11.3 (60-100)	.582*

SD, standard deviation.

\*Student's *t*-test. \*\*Mann-Whitney test.



probably be a result of increased comfort while eating, and the feeling of less insecurity and embarrassment. This improvement occurred earlier in the IL than in the DL group, due to the immediate placement of a temporary restoration. The low OHIP-14 score may be explained by generally healthy patients with good oral status and overall well-functioning prosthetic restorations. Others have reported high scores when patients are asked to judge the aesthetic outcome of the given restoration, in contrast to a more critical judgment by the dentists.<sup>29</sup> Factors of paramount importance for the patient's satisfaction may differ from the attitudes of the professionals.<sup>30</sup> Furthermore, there was a moderate correlation between VAS and OHIP-14, suggesting that low OHRQoL scores affect the patient's judgment of aesthetics in a negative sense.

An important limitation of this study is the short follow-up time (1 year). Further follow-up appointments would provide long-term data on the immediate loading protocol and the evaluated implant system. Moreover, only implants placed in the maxilla were evaluated. For further research, a volumetric evaluation of soft tissue alterations during the healing phase would possibly present more precise information.

The authors believe that new research efforts should be concentrated in a comparison between immediate loading with a flapless procedure and delayed loading with no intermediate restoration.

## 5 | CONCLUSION

This prospective randomized study showed that single implants in the maxilla can present satisfactory results with regard to either immediate loading or delayed loading after 12 months. With comparable MBL, soft-tissue, aesthetic, and patient-centered outcomes.

## ACKNOWLEDGMENT

The present study was funded by Region Skåne and Folkandvården Skåne AB (Public Dental Care Service, Skania, Sweden).

## CONFLICT OF INTEREST

We certify that we have no affiliation with or financial involvement in any organization or entity with direct financial interest in the subject matter or materials discussed in the manuscript, and that the material is original and has not been published elsewhere. The authors have no conflict of interest relevant to the content of the submission.

## REFERENCES

- [1] Jung RE, Zembic A, Pjetursson BE, Zwahlen M, Thoma DS. Systematic review of the survival rate and the incidence of biological, technical, and aesthetic complications of single crowns on implants reported in longitudinal studies with a mean follow-up of 5 years. *Clin Oral Implants Res.* 2012;23:2–21.
- [2] Beikler T, Flemmig TF. EAO consensus conference: economic evaluation of implant-supported prostheses. *Clin Oral Implants Res.* 2015; 26:57–63.
- [3] De Bruyn H, Raes S, Östman P-O, Cosyn J. Immediate loading in partially and completely edentulous jaws: a review of the literature with clinical guidelines. *Periodontol 2000.* 2014;66:153–187.
- [4] Atieh MA, Atieh AH, Payne AGT, Duncan WJ. Immediate loading with single implant crowns: a systematic review and meta-analysis. *Int J Prosthodont.* 2009;22:378–387.
- [5] Benic GI, Mir-Mari J, Hämmerle CHF. Loading protocols for single-implant crowns: a systematic review and meta-analysis. *Int J Oral Maxillofac Implants.* 2014;29:222–238.
- [6] Vandeweghe S, Cosyn J, Thevissen E, Van den Berghe L, De Bruyn H. A 1-year prospective study on Co-Axis® implants immediately loaded with a full ceramic crown. *Clin Implant Dent Relat Res.* 2012; 14:126–138.
- [7] Raes F, Cosyn J, Crommelinck E, Coessens P, De Bruyn H. Immediate and conventional single implant treatment in the anterior maxilla: 1-year results of a case series on hard and soft tissue response and aesthetics. *J Clin Periodontol.* 2011;38:385–394.
- [8] Cooper LF, Reside GJ, Raes F, et al. Immediate provisionalization of dental implants placed in healed alveolar ridges and extraction sockets: a 5-year prospective evaluation. *Int J Oral Maxillofac Implants.* 2014;29:709–717.
- [9] Esposito M, Barausse C, Pistilli R, et al. Immediate loading of post-extractive versus delayed placed single implants in the anterior maxilla: outcome of a pragmatic multicenter randomised controlled trial 1-year after loading. *Eur J Oral Implantol.* 2015;8:347–358.
- [10] den Hartog L, Raghoobar GM, Stellingsma K, Vissink A, Meijer HJA. Immediate non-occlusal loading of single implants in the aesthetic zone: a randomized clinical trial: immediate loading of anterior single implants. *J Clin Periodontol.* 2011;38:186–194.
- [11] Luongo G, Bressan E, Grusovin MG, et al. Do repeated changes of abutments have any influence on the stability of peri-implant tissues? Four-month post-loading preliminary results from a multicentre randomised controlled trial. *Eur J Oral Implantol.* 2015;8: 129–140.
- [12] Jemt T. Regeneration of gingival papillae after single-implant treatment. *Int J Periodontics Restorative Dent.* 1997;17:326–333.
- [13] Furhauser R, Florescu D, Benesch T, Haas R, Mailath G, Watzek G. Evaluation of soft tissue around single-tooth implant crowns: the pink esthetic score. *Clin Oral Implants Res.* 2005;16:639–644.
- [14] Belser UC, Grütter L, Vailati F, Bornstein MM, Weber H-P, Buser D. Outcome evaluation of early placed maxillary anterior single-tooth implants using objective esthetic criteria: a cross-sectional, retrospective study in 45 patients with a 2- to 4-year follow-up using pink and white esthetic scores. *J Periodontol.* 2009;80:140–151.
- [15] Hägglin C, Berggren U, Hakeberg M, Edvardsson A, Eriksson M. Evaluation of a Swedish version of the OHIP-14 among patients in general and specialist dental care. *Swed Dent J.* 2007;31:91–101.
- [16] World Medical Association. Revising the declaration of Helsinki. *Bull Med Ethics.* 2000;158:9–11.
- [17] Lekholm U, Zarb GA. Patient selection and preparation In: Branemark PI, Zarb GA, Albrektsson T, eds. *Tissue-Integrated Prostheses: Osseointegration in Clinical Dentistry.* Chicago: Quintessence Publishing Co; 1985:199–209.
- [18] den Hartog L, Raghoobar GM, Stellingsma K, Meijer HJA. Immediate loading and customized restoration of a single implant in the maxillary esthetic zone: a clinical report. *J Prosthet Dent.* 2009;102:211–215.
- [19] Löe H, Silness J. Periodontal disease in pregnancy. I. Prevalence and severity. *Acta Odontol Scan.* 1963;21:533–551.
- [20] Cosyn J, Eghbali A, De Bruyn H, Dierens M, De Rouck T. Single implant treatment in healing versus healed sites of the anterior

- maxilla: an aesthetic evaluation: early and conventional single implants. *Clin Implant Dent Relat Res*. 2012;14:517–526.
- [21] Albrektsson T. On long-term maintenance of the osseointegrated response. *Aust Prosthodont J*. 1993;7:15–24.
- [22] Derks J, Håkansson J, Wennström JL, Tomasi C, Larsson M, Berglundh T. Effectiveness of implant therapy analyzed in a Swedish population: early and late implant loss. *J Dental Res*. 2015;94:44S–51S.
- [23] Guarnieri R, Grande M, Ippoliti S, Iorio-Siciliano V, Riccitiello F, Faronato D. Influence of a laser-Lok surface on immediate functional loading of implants in single-tooth replacement: three-year results of a prospective randomized clinical study on soft tissue response and esthetics. *Int J Periodontics Restorative Dent*. 2015;35:865–875.
- [24] Huang H, Wismeijer D, Shao X, Wu G. Mathematical evaluation of the influence of multiple factors on implant stability quotient values in clinical practice: a retrospective study. *Ther Clin Risk Manag*. 2016;12:1525–1532.
- [25] Naert I, Duyck J, Hosny M, Jacobs R, Quirynen M, van Steenberghe D. Evaluation of factors influencing the marginal bone stability around implants in the treatment of partial edentulism. *Clin Implant Dent Relat Res*. 2001;3:30–38.
- [26] Wittneben J-G, Buser D, Belser UC, Brägger U. Peri-implant soft tissue conditioning with provisional restorations in the esthetic zone: the dynamic compression technique. *Int J Periodontics Restorative Dent*. 2013;33:447–455.
- [27] Sculean A, Gruber R, Bosshardt DD. Soft tissue wound healing around teeth and dental implants. *J Clin Periodontol*. 2014;41: S6–22.
- [28] Raes F, Cosyn J, De Bruyn H. Clinical, aesthetic, and patient-related outcome of immediately loaded single implants in the anterior maxilla: a prospective study in extraction sockets, healed ridges, and grafted sites. *Clin Implant Dent Relat Res*. 2013;15:819–835.
- [29] Cosyn J, Eghbali A, Hanselaer L, et al. Four modalities of single implant treatment in the anterior maxilla: a clinical, radiographic, and aesthetic evaluation: four modalities of single implant treatment. *Clin Implant Dent Relat Res*. 2013;15:517–530.
- [30] Chang M, Odman PA, Wennström JL, Andersson B. Esthetic outcome of implant-supported single-tooth replacements assessed by the patient and by prosthodontists. *Int J Prosthodont*. 1999;12: 335–341.

**How to cite this article:** Gjelvold B, Kisch J, Chrcanovic BR, Albrektsson T, Wennerberg A. Clinical and radiographic outcome following immediate loading and delayed loading of single-tooth implants: Randomized clinical trial. *Clin Implant Dent Relat Res*. 2017;00:1–10. <https://doi.org/10.1111/cid.12479>