

Histologic evaluation of bone healing of adjacent alveolar sockets grafted with bovine- and porcine-derived bone: a comparative case report in humans

Renzo **Guarnieri**^{1,*}, Patricia **DeVilliers**² and Maurizio **Grande**³

1Private Periodontal and Implant Practice, Roma, Treviso, Italy, 2Adjunct Assistant Professor of Pathology, University of Alabama at Birmingham, Birmingham, AL, USA and 3Private Dental Implant Practice, Roma, Italy

*Correspondence address. Via A. Moro 3, 31022 Preganziol Treviso, Italy. Tel: +39-342-5224458; E-mail: renzoguarnieri@gmail.com

Received 21 November 2016; revised 4 January 2017; accepted on 7 January 2017

Abstract

Purpose: To evaluate and compare histomorphometrically the bone response to two xenografts, one bovine and the other porcine, grafted in adjacent extraction sockets in a human. *Materials and methods:* In this case report, two adjacent maxillary premolars were extracted, and the sockets were filled with two different xenogeneic bone substitutes (first premolar with bovine bone, and second premolar with porcine bone) to counteract post-extraction volume loss. Following 6 months bone core specimens were harvested during the placement of implants at the regenerated sites.

Results: Histomorphometrically, for the bovine xenograft the percentage of newly formed bone (osteoid) was 26.85%, the percentage of the residual graft material was 17.2% and the percentage of connective tissue 48.73%, while for the porcine xenograft, newly formed bone (osteoid) represented 32.19%, residual graft material was 6.57% and non-mineralized connective tissue was 52.99%. *Conclusions:* Histological results indicated that both biomaterials assessed in this study as grafts for socket preservation technique are biocompatible and osteoconductive. Bovine bone derived demonstrated to be less resorbable than porcine bone derived. Both xenogenic biomaterials did not interfere with the normal bone reparative processes.

Keywords: socket preservation; bovine bone-derived; porcine bone-derived; histology

Introduction

The spontaneous process of bone healing after tooth extraction has been studied in human models [1–7]. It is characterized by a physiological process of bone remodeling and reabsorption, which occurs rapidly and can determine in the first 6 months the loss of about 40% of the height and 60% of the width of the alveolar bone [8–10]. Because the best period to preserve the alveolar ridge is at the time of extraction [6, 10, 11], socket preservation technique has been proposed as a means of counteracting the post-extraction volume loss [12–14]. Many graft materials such as autogenous bone, allografts, xenografts and alloplasts, associated or not with absorbable and non-absorbable membranes, have been used for extraction socket preservation in an attempt to maintain the dimensions of the alveolar ridge following extraction [15]. Grafting materials,

remaining in place during the whole bone healing period, provide a mechanical support preventing the remodeling pattern observed at the non-grafted extraction socket. In order to avoid harvesting an autograft, and thereby eliminating additional surgical procedures and risks, xenografts have been proven as alternative filler materials to be used for socket preservation. Bovine bone-derived is by far the most commonly used and researched xenogeneic bone graft. It has been tested in several randomized clinical trials and is thus one of the best-documented biomaterials. Porcine derived-bone has been recently also considered as graft biomaterial for bone regeneration [16–20]. Bovine and porcine bone-derived have shown to be osteoconductive [21, 22]. Nevertheless, controversy remains, whether both xenografts are truly resorbable [20, 22]. Non-resorption might result in shielding of the newly formed bone from physiological stresses necessary for further remodeling and maturation.

In addition, the presence of residual xenogeneic particles surrounded by connective tissue and/or bone tissue might indicate that xenogeneic material in post-extraction sockets grafting technique could interfere with the normal healing process.

The aim of any bone grafting technique is to achieve formation of 100% living and reactive tissue able to undergo a sustained state of remodeling to maintain the mechanical and the biologic function over time. The purpose of the current study was to evaluate in humans the histological bone healing of adjacent alveolar sockets grafted with bovine and porcine xenogeneic bone.

Materials and methods

The patient was a 50-year-old female (Fig. 1) with no systemic disorders. The extraction of a maxillary first and second premolar was scheduled followed by restoration with implants at the later stage (6 months after extraction and socket preservation).

Surgical procedure

The identified teeth were extracted in a minimally traumatic manner with periostomes and either no flap or minimal flap reflection no more than 2 mm beyond the alveolar crest, followed by curettage and irrigation of the socket. The randomly selected graft material (bovine/porcine bone-derived) was hydrated with sterile saline. As randomization result, the socket of the first maxillary premolar was filled with bovine bone derived biomaterial (Laddec®, BioHorizons, Birmingham, AL, USA), and the socket of the second maxillary premolar was filled with porcine bone derived biomaterials (MinerOss XP®, BioHorizons, Birmingham, AL, USA). A resorbable porcine derived collagen membrane (Pliable®, BioHorizons, Birmingham, AL, USA), was placed over the graft material and was secured over the socket orifice with non resorbable sutures. Laddec® and MinerOss XP® are commercially available biomaterials. Both are obtained using a process which involves an extensive washing with distilled water and phosphate buffer 0.4 mol/l, pH 7.4, followed by defatting at a temperature < 50°C with ethanol/dichloromethane and proteoglycan removal by urea and mercaptoethanol.

Flaps were not reflected since a dehiscence was not detected. Post-operative instructions were given and 500 mg of amoxicillin three times daily for 1 week, were prescribed. The patient was instructed to rinse for 30 s twice daily with 0.12% chlorhexidine gluconate for 2 weeks. Sutures were removed 2 weeks after the socket preservation procedure was completed. At 6 months, bone core samples from the extraction sockets, which were grafted with xenogeneic bone materials, were taken for histological examination, at the same time that implants were placed.

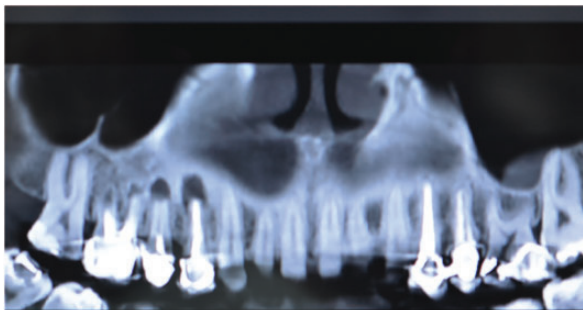


Figure 1. Radiograph of the patient

Histologic analysis

The bone specimens were immediately fixed in 10% buffered formalin and embedded in a glycolmethacrylate resin. After polymerization, specimens were sectioned along their longitudinal axis to a thickness of 70 microns (plastic Microtome, RM 2265). Slides were stained with trichrome, and examined using an Olympus B51 microscope. The histomorphometry was performed using Bioquant® image analysis software (R&M Biometrics, Nashville, TN, USA) and images were captured with a Q-Imaging camera, 32-0013B-157, RETIGA, Colour 12-bit.

Results

The specimens harvested from both extraction sites exhibited the trabecular bone pattern with lamellar and woven bone and surfaced by osteoid, and marrow spaces filled with adipocytes and a few inflammatory cells. The bone cores reveal minimal inflammatory response with no foreign body inflammatory reaction or fibrous encapsulation of the bovine or porcine bone spicules. Histomorphometrically, between the two xenografts were found no significant differences in newly formed bone (osteoid), whereas differences in the residual graft material and non-mineralized connective tissue were present (Figs 2–5 and Table 1). For bovine xenogeneic the amount of newly formed bone (osteoid), of residual graft, and of connective tissue was 26.85, 17.2 and 48.73%, respectively. For the porcine xenograft newly formed bone (osteoid) represented 32.19%, residual graft material 6.57% and non-mineralized connective tissue 52.99%. The percentages of total trabecular bone were significantly higher in the extraction socket grafted with porcine xenograft than in the extraction socket grafted with bovine xenograft. Moreover, the porcine graft biomaterial showed a higher resorption percentage than the bovine xenograft.

Discussion

Xenogeneic bone has been proposed in extraction socket grafting technique to counteract the bone changes after tooth extraction. The graft biomaterial allows to stabilize the coagulum within the socket, counteracting the risk of reduction of the hard tissue volume. In addition, it provides a scaffold for the ingrowth of cellular and vascular

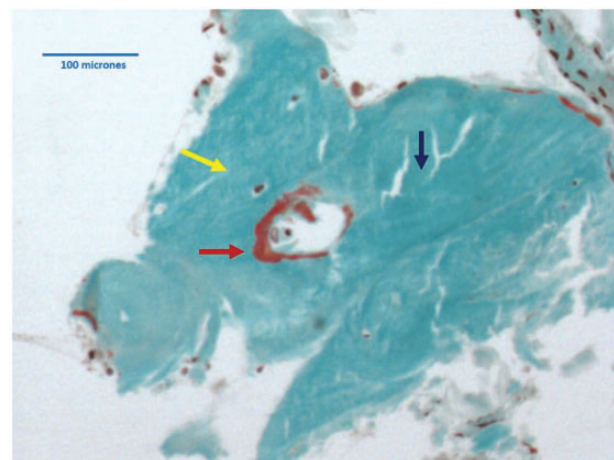


Figure 2. Histologic section of extraction socket grafted with bovine bone (Trichrome stain X 10): blue arrow = residual graft material, yellow arrow = viable bone, red arrow = newly formed bone (osteoid)

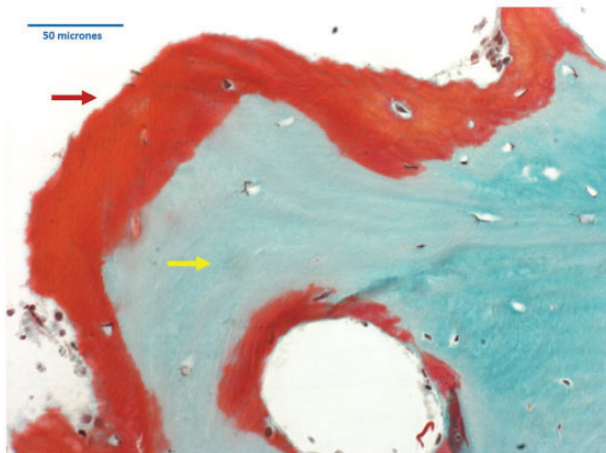


Figure 3. Histologic section of extraction socket grafted with bovine bone (Trichrome stain X 20): yellow arrow = viable bone, red arrow = newly formed bone (osteoid)

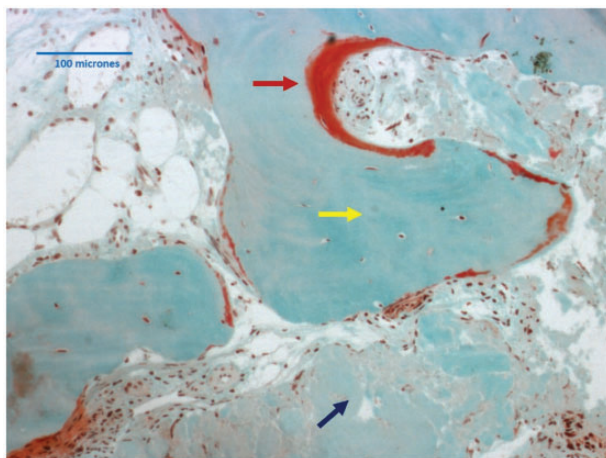


Figure 4. Histologic section of extraction socket grafted with porcine bone (Trichrome stain X 10): blue arrow = residual graft material, yellow arrow = viable bone, red arrow = osteoid

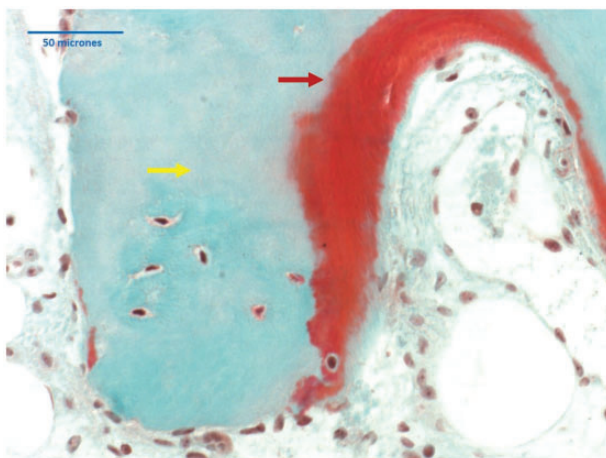


Figure 5. Histologic section of extraction socket grafted with porcine bone (trichrome stain X 20): yellow arrow = viable bone, red arrow = osteoid

Table 1. Histomorphometric data

Site	Bovine derived bone	Porcine derived bone
Tt. area of bone	3.49	2.46
Tt. area of bone graft	2.24	0.50
Tt. osteoid area	0.629	0.935
Tt. connective tissue area	6.34	4.05
% . connective tissue./Tt. area	48.73	52.99
% . Bone/Tt. tissue area	2.85	32.19
% . Graft/Tt. tissue area	17.24	6.57
% . Osteoid/Tt. tissue area	7.18	8.24

components to form new bone. Araújo *et al.* [23] explained the different histologic phases of bone healing following the placement of a xenogenic graft in the fresh extraction socket. The first phase of the process is characterized by a non-specific action: a blood clot is formed in the injured area where the outer area of the local bone becomes necrotic, the capillaries start to develop, and migration of inflammatory cells, e.g. lymphocytes, granulocytes and monocytes occurs. These actions restore blood flow, activate an inflammatory response after 1–3 days, and start to form granulation tissue. During this phase, a fibrin network of the coagulum incorporates the bio-material, the surface of which begins to be covered by a layer of neutrophilic leukocytes. The granulation tissue will mature to a collagen matrix and mesenchymal stem cells begin to differentiate into osteoblasts cells. One to two weeks later, begins a second phase characterized by a more specific action depending by ability of mesenchymal cells to migrate onto the biomaterial surface, and to differentiate themselves in osteoblast.

The absence of significant inflammatory response, documented in the present study by a low number of inflammatory cells, confirms the biocompatibility and the osteointegrative capacity of both xenogenic materials tested. Our results are in agreement with previously reported data [21, 22], indicating the osteoconductive capacity of porcine and bovine xenografts, which acted as scaffolding for bone regeneration.

Both the bovine and porcine bone derived biomaterials are processed to remove their antigenicity. With the removal of the organic component, concerns about immunological reactions become non-existent. However, it has been showed that the remaining anorganic structure provides a natural architectural able of providing a mechanical support to counteract the tissue changes, and of preserving the height and the widths of the alveolar bone [13, 14].

The xenogenic materials used in the present study are characterized by different physical features, presenting the bovine bone an average of pore sizes of $342.9 \pm 105.6 \mu\text{m}$, a strut thickness of 164.8 ± 35.1 , and a pore connectivity of 72–80%, and the porcine bone a mean pore size of $474.2 \pm 76.2 \mu\text{m}$, a strut thickness of $121.7 \pm 21.9 \mu\text{m}$ and a pore connectivity of 88–95%.

These differences might explain the different resorption rate evident between the two xenogenic biomaterial. It is been previously reported that the resorption process of xenogenic biomaterial may be the result of several factors, among which the pore size, the pore morphology, the pore percentage, the connection between pores and the granulometry [24, 25]. Van Blitterswijk *et al.* [25] reported a correlation between the pore size and the granulometry with the quantity of neo-formed osseous tissue. Results of the study showed that a mean pore size of 130 mm is correlated with a 17% degree of bone formation, which rises progressively with the increase of the

porosity. In addition, others authors [26] reported that the bone neo formation within the biomaterial granules is correlated with the degree of interporosity. These data are in agreement with results of the present study, since the histological sections harvested from by the bone core harvested at the extraction socket grafted with porcine derived biomaterial, showed a higher bone growth and a higher percentage of osteoid tissue both in surface pores, both within the granules

Differences in graft integration and reabsorption depend also by the interconnectivity [27]. A decrease in pore connectivity could influence both the possibility that a greater number of osteoblasts can penetrate the porous structure, both the degree of angiogenesis and the resulting flux of nutrient and of oxygen [28]. Moreover, it has been suggested that the interconnected microporosity could also affect the level of intimacy between osteoblastic cells and the hydroxyapatite [29]. The higher percentage of pore connectivity present in the porcine bone, compared to that of the bovine bone, could also explain the greater degree of resorption of this biomaterial documented in the present study.

Conclusion

The xenogenic biomaterials investigated in this study were found to be biocompatible and osteoconductive. Bovine xenograft showed less resorbable than porcine xenograft. Both xenogenic biomaterials, when used as grafts in socket preservation technique, do not interfere with the normal bone reparative processes.

Funding

AQ4 Conflict of interest statement. None declared.

References

- Claffin RS. Healing of disturbed and undisturbed extraction wounds. *J Am Dent Ass* 1936; 23:945–59.
- Mangos JF. The healing of extraction wounds. An experimental study based on microscopic and radiographic investigations. *New Zealand Dent J* 1941; 37:4–24.
- Christopher ER. Histological study of bone healing in relation to the extraction of teeth. *Northw Univ Bull* 1942; 45:5.
- Amler MH. The time sequence of tissue regeneration in human extraction wounds. *Oral Surg Oral Med Oral Pat* 1969; 27:309–18.
- Amler MH, Johnson PL, Salman I. Histological and histochemical investigation of human alveolar socket healing in undisturbed extraction wounds. *J Am Dent Ass* 1960; 61:32–44.
- Boyne PJ. Osseous repair of the postextraction alveolus in man. *Oral Surg Oral Med Oral Pat* 1966; 21:805–13.
- Trombelli L, Farina R, Marzola A et al. Modeling and remodeling of human extraction sockets. *J Clin Periodontol* 2008; 35:630–9.
- Van der Weijden F, Dell'Acqua F, Slot DE. Alveolar bone dimensional changes of post-extraction sockets in humans: a systematic review. *J Clin Periodontol* 2009; 36:1048–58.
- Johnson K. A study of the dimensional changes occurring in the maxilla following tooth extraction. *Aust Dent J* 1969; 14:241–4.
- Atieh MA, Alsabeeha NH, Payne AG, Duncan W, Faggion CM, Esposito M. Interventions for replacing missing teeth: alveolar ridge preservation techniques for dental implant site development. *Cochrane Database Syst Rev* 2015; 5:CD010176.
- Iocca O, Farcomeni A, Pardiñas Lopez S, Talib HS. Alveolar ridge preservation after tooth extraction: a Bayesian Network meta-analysis of grafting materials efficacy on prevention of bone height and width reduction. *J Clin Periodontol* 2017; 44:104–14.
- Mardas N, Trullenque-Eriksson A, MacBeth N, Petrie A, Donos N. Does ridge preservation following tooth extraction improve implant treatment outcomes: a systematic review: Group 4: Therapeutic concepts & methods. *Clin Oral Implants Res* 2015; 26 Suppl 11:180–201.
- Jamjoom A, Cohen RE. Grafts for ridge preservation. *J Funct Biomater* 2015; 6:833–48.
- Masaki C, Nakamoto T, Mukaibo T et al. Strategies for alveolar ridge reconstruction and preservation for implant therapy. *J Prosthodont Res* 2015; 59:220–8.
- De Risi V, Clementini M, Vittorini G et al. Alveolar ridge preservation techniques: a systematic review and meta-analysis of histological and histomorphometrical data. *Clin Oral Implants Res* 2015; 26:50–68.
- Barone A, Ricci M, Calvo-Guirado JL et al. Bone remodelling after regenerative procedures around implants placed in fresh extraction sockets: an experimental study in beagle dogs. *Clin Oral Implants Res* 2011; 22:1131–7.
- Barone A, Toti P, Quaranta A, Alfonsi F, Cucchi A, Negri BD, Felice R, Marchionni S, Calvo-Guirado JL, Covani U, Nannmark U. Tissue Changes after ridge preservation with two xenografts: preliminary results from a multicenter randomized controlled clinical trial. *J Clin Periodontol* 2017; doi: 10.1111/jcpe.12655.
- Calvo Guirado JL, Ramírez Fernández MP, Negri B et al. Experimental model of bone response to collagenized xenografts of porcine origin (OsteoBio® mp3): a radiological and histomorphometric study. *Clin Implant Dent Relat Res* 2013; 15:143–51.
- Pagliani L, Andersson P, Lanza M et al. A collagenated porcine bone substitute for augmentation at neoss implant sites: a prospective 1-year multicenter case series study with histology. *Clin Implant Dent Relat Res* 2012; 14:746–58.
- Piattelli M, Favero GA, Scarano A et al. Bone reactions to anorganic bovine bone (Bio-Oss) used in sinus augmentation procedures: a histologic long-term report of 20 cases in humans. *Int J Oral Maxillofac Implants* 1999; 14:835–40.
- de Misquita MR, Bentini R, Goncalves F. The performance of bone tissue engineering scaffolds in in vivo animal models: a systematic review. *J Biomater Appl* 2016; 31:625–36.
- Calvo-Guirado JL, Aguilar-Salvatierra A, Ramírez-Fernández MP et al. Bone response to collagenized xenografts of porcine origin (mp3®) and a bovine bone mineral grafting (4BONE™) XBM) grafts in tibia defects: experimental study in rabbits. *Clin Oral Implants Res* 2016; 27:1039–46.
- Araujo MG, Liljenberg B, Lindhe J. Dynamics of Bio-Oss Collagen incorporation in fresh extraction socket: an experimental study in the dog. *Clin Oral Implants Res* 2008; 19:1111–8.
- Hing KA, Best SM, Tanner KE et al. Mediation of bone ingrowth in porous hydroxyapatite bone graft substitutes. *J Biomater Res Part A* 2004; 68:187–200.
- van Blitterswijk CA, Grote JJ, Kuijpers W et al. Macropore tissue ingrowth: a quantitative and qualitative study on hydroxyapatite ceramic. *Biomaterials* 1986; 7:137–43.
- Wang W, Itoh S, Tanaka Y et al. Comparison of enhancement of bone ingrowth into hydroxyapatite ceramics with highly and poorly interconnected pores by electrical polarization. *Acta Biomater*. 2009; 5:3132–40.
- Tamai N, Myoui A, Tomita T et al. Novel hydroxyapatite ceramics with an interconnective porous structure exhibit superior osteoconduction in vivo. *J Biomed Mater Res* 2002; 59:110–7.
- Yumada Y, Tamura T, Hariu K et al. Angiogenesis in newly augmented bone observed in rabbit calvarium using a titanium cap. *Clin Oral Implants Res* 2008; 19:1003–9.
- Motomiya M, Ito M, Takahata K et al. Effect of hydroxylapatite porous characteristics on healing outcomes in rabbit posterolateral spinal fusion model. *Eur Spine J* 2007; 16:2215–24.

Journal: *Regenerative Biomaterials*
Article Doi: 10.1093/rb/rbx002
Article Title: Histologic evaluation of bone healing of adjacent alveolar sockets grafted with bovine- and porcine-derived bone: a comparative case report in humans
First Author: Renzo Guarnieri
Corr. Author: Renzo Guarnieri

OXFORD
UNIVERSITY PRESS

INSTRUCTIONS

We encourage you to use Adobe's editing tools (please see the next page for instructions). If this is not possible, reply to this message and send a list of corrections listing each change in the following manner: line number, current text, change to be made.

Changes should be corrections of typographical errors only. Changes that contradict journal style will not be made.

These proofs are for checking purposes only. They should not be considered as final publication format. The proof must not be used for any other purpose. In particular we request that you do not post them on your personal/institutional web site, and do not print and distribute multiple copies. Neither excerpts nor all of the article should be included in other publications written or edited by yourself until the final version has been published and the full citation details are available. You will be sent these when the article is published, along with an author PDF of the final article.

- 1. License to Publish:** If you have not already done so, please visit the link in your Welcome email and complete your License to Publish online.
- 2. Author groups:** Please check that all names have been spelled correctly and appear in the correct order. Please also check that all initials are present. Please check that the author surnames (family name) have been correctly identified by a pink background. If this is incorrect, please identify the full surname of the relevant authors. Occasionally, the distinction between surnames and forenames can be ambiguous, and this is to ensure that the authors' full surnames and forenames are tagged correctly, for accurate indexing online. Please also check all author affiliations.
- 3. Figures:** Figures have been placed as close as possible to their first citation. Please check that they have no missing sections and that the correct figure legend is present.
- 4. Missing elements:** Please check that the text is complete and that all figures, tables, and their legends are included.
- 5. Funding:** Please detail any funding received in the Acknowledgments paragraph. Please ensure that you use the full official name of the funding body, and if your paper has received funding from any institution, such as NIH, please inform us of the grant number to go into the Acknowledgments paragraph. We use the institution names to tag NIH-funded articles so they are deposited at PMC. If we already have this information, we will have tagged it and it will appear as colored text in the Acknowledgments paragraph. Please check the information is correct.
- 6. Permissions:** Permission to reproduce any third party material in your paper should have been obtained prior to acceptance. If your paper contains figures or text that require permission to reproduce, please email as soon as possible.

Author Query Form

Journal: ***Regenerative Biomaterials***
Article Doi: 10.1093/rb/rbx002
Article Title: **Histologic evaluation of bone healing of adjacent alveolar sockets grafted with bovine- and porcine-derived bone: a comparative case report in humans**
First Author: **Renzo Guarnieri**
Corr. Author: **Renzo Guarnieri**

AUTHOR QUERIES – TO BE ANSWERED BY THE CORRESPONDING AUTHOR

The following queries have arisen during the typesetting of your manuscript. Please click on each query number and respond by indicating the change required within the text of the article. If no change is needed please add a note saying “No change.”

- AQ1: Please check that all names have been spelled correctly and appear in the correct order. Please also check that all initials are present. Please check that the author surnames (family name) have been correctly identified by a pink background. If this is incorrect, please identify the full surname of the relevant authors. Occasionally, the distinction between surnames and forenames can be ambiguous, and this is to ensure that the authors' full surnames and forenames are tagged correctly, for accurate indexing online. Please also check all author affiliations.
- AQ2: Please check that the text is complete and that all figures, tables and their legends are included.
- AQ3: Please check the accuracy of special characters, equations, dosages and units if applicable.
- AQ4: Please provide a Funding statement, detailing any funding received. Remember that any funding used while completing this work should be highlighted in a separate Funding section. Please ensure that you use the full official name of the funding body, and if your paper has received funding from any institution, such as NIH, please inform us of the grant number to go into the funding section. We use the institution names to tag NIH-funded articles so they are deposited at PMC. If we already have this information, we will have tagged it and it will appear as coloured text in the funding paragraph. Please check the information is correct.
- AQ5: Figure has been placed as close as possible to its first citation. Please check that it has no missing sections and that the correct figure legend is present.
- AQ6: Please note, figures supplied in colour will be published online, in colour, free of charge.
- AQ7: Please check whether the short title is OK as set.
- AQ8: Please provide the department and University/Institute names in affiliations.
- AQ9: Please provide the fax number and check whether the correspondence address is OK as given.